

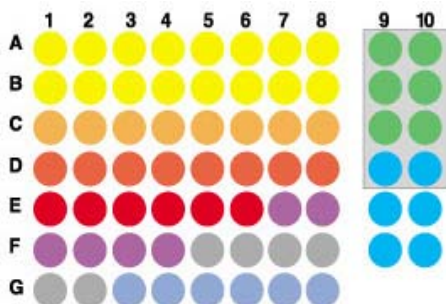
Specifications:

- No. of cases: 31
- Tissue type: Kidney and ureter cancer tissues
(kidney:28, ureter:3)
- No. of spots: 2 spots from each cancer case (62 spots)
6 non-neoplastic spots (6 spots)
- Total spots: 68
- Corresponding normal tissues with cancers: Yes
- Diameter: 1.0 mm

Documents:

- Product specification: layout, summary of tissue spots
- H&E stained images
- Detailed pathological information

Layout:

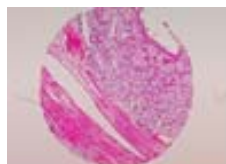


- non-neoplastic
- RCC, conventional type
- RCC, papillary type
- RCC, chromophobe type
- RCC, sarcomatoid
- oncocy toma
- Wilm's tumor
- angiomyolipoma
- urethelial carcinoma
- ureter

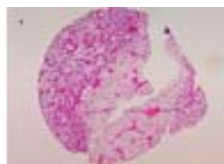
Summary of tissue spots

No.	Coordinate	Sex	Age	Key Word	Grade	TNM Stage	
1	A	1,2	M	45	RCC.conventional type	1	T1aN0M0 (I)
2		3,4	M	63	RCC.conventional type	1	T2N0M0 (II)
3		5,6	F	65	RCC.conventional type	2	T3bN0M0 (III)
4		7,8	M	67	RCC.conventional type	2	T1bNxM1 (IV)
5		9,10	F	70	urothelial ca		T2N0M0 (II)
6	B	1,2	M	62	RCC.conventional type	3	T3bN0M0 (III)
7		3,4	M	65	RCC.conventional type	3	T3bN0M1 (IV)
8		5,6	M	71	RCC.conventional type	4	T3bN0M0 (III)
9		7,8	M	28	RCC.conventional type	4	T2N0M1 (IV)
10		9,10	F	74	urothelial ca		T2N0M0 (II)
11	C	1,2	M	44	RCC.papillary type	2	T2N0M0 (II)
12		3,4	M	71	RCC.papillary type	3	T1bN0M0 (I)
13		5,6	M	52	RCC.papillary type	3	T1aN0M0 (I)
14		7,8	M	46	RCC.papillary type	3	T3aN2M1 (IV)
15		9,10	M	79	urothelial ca		TaN0M0 (0a)
16	D	1,2	F	57	RCC.chromophobe type	2	T3aN0M0 (III)
17		3,4	F	36	RCC.chromophobe type		T1bN0M0 (I)
18		5,6	F	55	RCC.chromophobe type		T1bN0M0 (I)
19		7,8	M	74	RCC.chromophobe type		
20		9	F	36	Ureter		
21	10	F	70	Ureter			
22	E	1,2	M	48	RCC.sarcomoid type		T3bN0M0 (III)
23		3,4	F	66	RCC.sarcomoid type		
24		5,6	F	58	RCC.sarcomoid type		
25		7,8	F	59	oncocytoma	1	
26		9	F	61	Kideny		
27		10	F	2	Kideny		
28	F	1,2	F	61	oncocytoma		
29		3,4	F	62	oncocytoma		
30		5,6	F	2	Wilm's tumor		
31		7,8	F	2	Wilm's tumor		
32		9	F	61	Kideny		
33		10	F	2	Kideny		
34	G	1,2	M	2	Wilm's tumor		
35		3,4	F	63	angiomyolipoma		
36		5,6	F	67	angiomyolipoma		
37		7,8	F	58	angiomyolipoma		

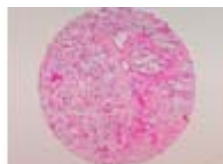QC sheet_LOT#122120401271
Hematoxylin and Eosin staining



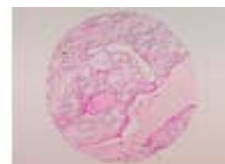A1



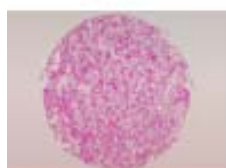A2



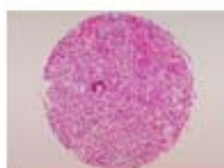A3



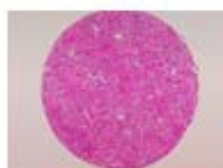A4



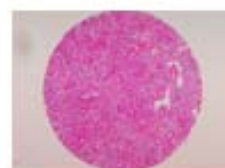A5



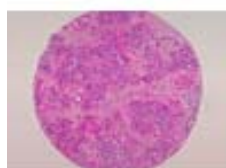
A6



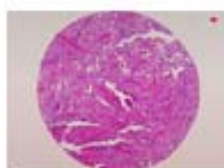
A7



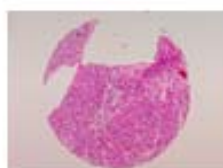
A8



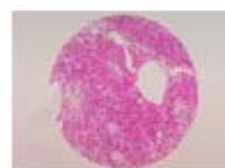A9



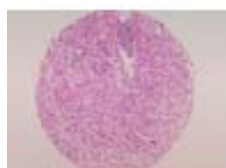A10



B1



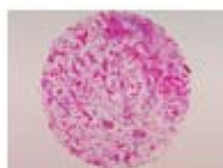B2



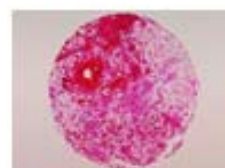
B3



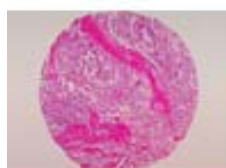B4



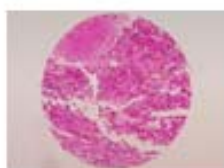B5



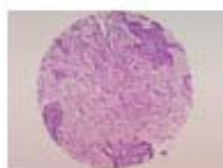B6



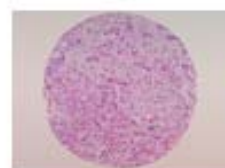
B7



B8



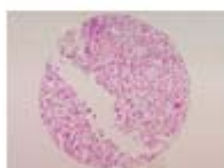B9



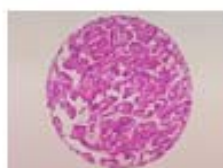B10



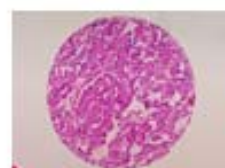C1



C2

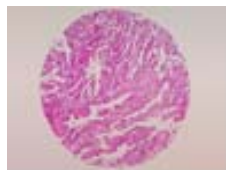

C3

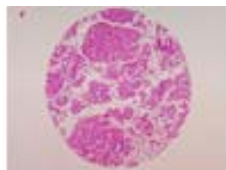


C4

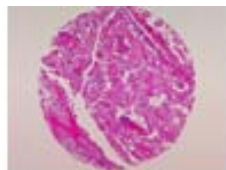
QC sheet_LOT#122120401271
Hematoxylin and Eosin staining



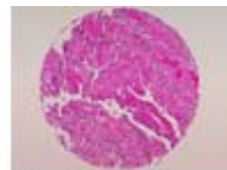
C5



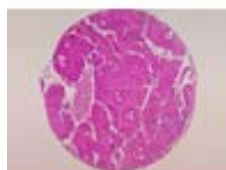
C6



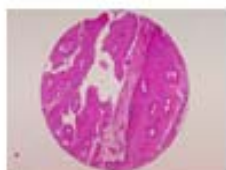C7



C8



C9



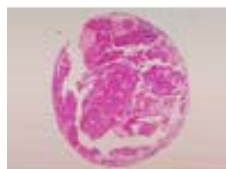
C10



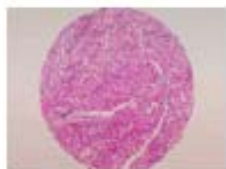D1



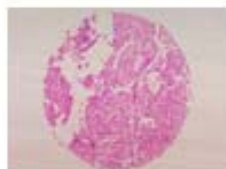
D2



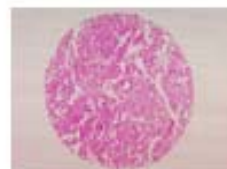
D3



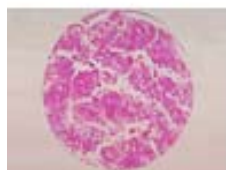
D4



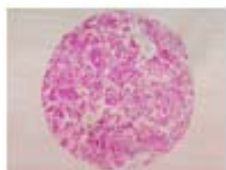
D5



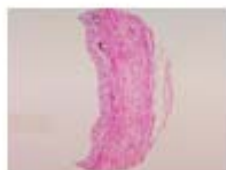D6



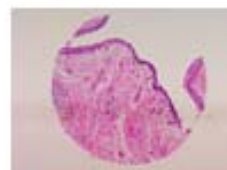D7



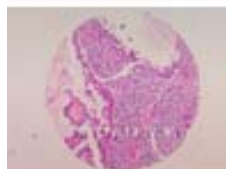
D8



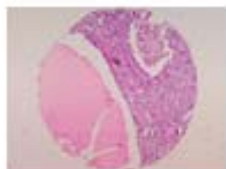
D9



D10



E1



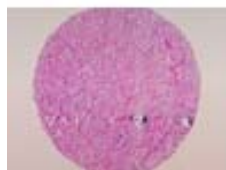D2



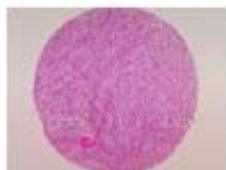D3



D4



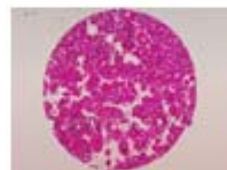
E5



E6

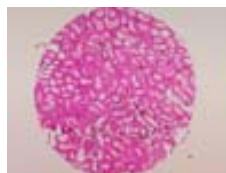

E7

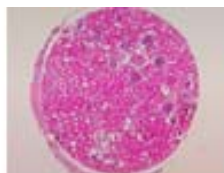


E8

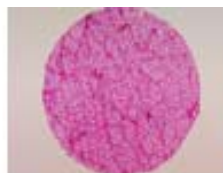QC sheet_LOT#122120401271 Hematoxylin and Eosin staining



E9



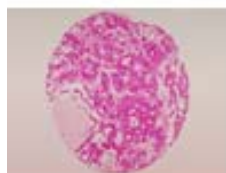E10



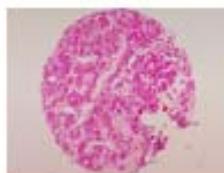
F1



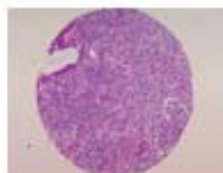
F2



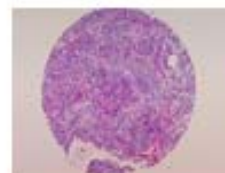
F3



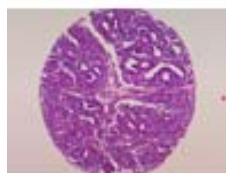F4



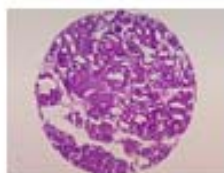
F5



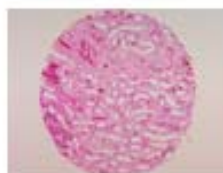F6



F7



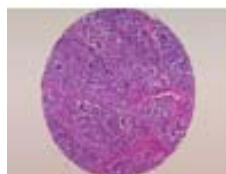F8



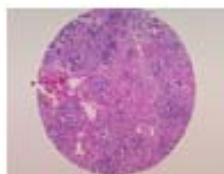
F9



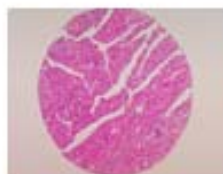
F10



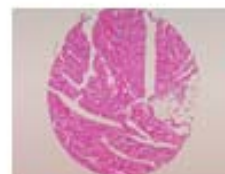
G1



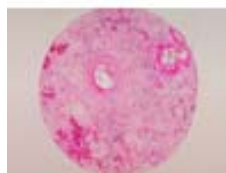
G2



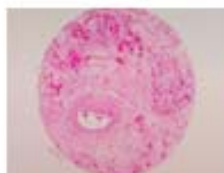G3



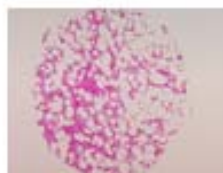
G4



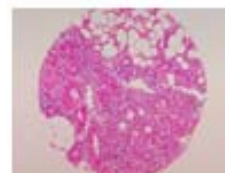
G5



G6



G7



G8

A214 : Kidney and ureter cancer tissues

No.	Coordinate		Sex	Age	Key Word	Histological Diagnosis	Grade	TNM Stage
1	A	1,2	m	45	RCC.conventional type	Intrauterine contents, D&E: product of conception	1	T1aN0M0 (I)
2	A	3,4	m	63	RCC.conventional type	1. Kidney, left, radical nephrectomy: renal cell carcinoma, 1) clear cell type 2) fuhrman's nuclear grade I 3) confined to renal capsule 4) no renal vein thrombosis 5) eosinophilic abscess 6) resection margin, ureteral: free of tumor 2. renal artery: marked intimal thickening with myointimal cell proliferation 3. Adrenal gland: free of tumor 1) regional lymph nodes, perirenal lymph nodes (0/2): free of tumor	1	T2N0M0 (II)
3	A	5,6	f	65	RCC.conventional type	1. Kidney, right, radical nephrectomy: renal cell carcinoma, conventional, 1) fuhrman grading II 2) confined within the capsule 3) tumor embolus in the renal vein 2. Ureter: free of tumor 3. Adrenal gland: free of tumor	2	T3bN0M0 (III)
4	A	7,8	m	67	RCC.conventional type	1. Kidney, right radical nephrectomy: renal cell carcinoma, 1) conventional clear cell type (fuhrman's nuclear grade II) 2) confined to renal capsule 3) resection margin, ureter: free of tumor 2. Blood vessel (renal vein and artery): free of tumor 3. Adrenal gland: free of tumor 4. Appendix, incidental appendectomy: no pathological diagnosis	2	T1bNxM1 (IV)

A214 : Kidney and ureter cancer tissues

No.	Coordinate		Sex	Age	Key Word	Histological Diagnosis	Grade	TNM Stage
5	A	9,10	f	70	urothelial ca	1. Ureter, left, nephroureterectomy: High grade urothelial carcinoma, 1) completely obliterating ureteral lumen 2) full thickness involvement of ureteral wall without reaching to serosa 3) resection margin, proximal and distal: free of tumor 2. Kidney: low grade chronic pyelonephritis 3. Adrenal gland: mild cortical hyperplasia		T2N0M0 (II)
6	B	1,2	m	62	RCC.conventional type	1. Kidney, left, radical nephrectomy: renal cell carcinoma, 1) conventional clear cell type 2) extension into perinephric fat tissue, but not beyond 3) gerota's fascia 4) renal vein involvement 5) fuhrman's nuclear grade III 2. Ureter, resection margin, adrenal gland: free of tumor 1) lymph nodes, paraaortic (0/5) : free of tumor	3	T3bN0M0 (III)
7	B	3,4	m	65	RCC.conventional type	1. Kidney, left, radical nephrectomy: renal cell carcinoma, conventional (clear cell) type, 1) confined within renal capsule 2) fuhrman's nuclear grade III 3) invasion to the renal vein 4) no pelvocaliceal system 5) simple cyst 2. Double uterus 1) resection margins, ureter and vessels: free of tumor 3. Adrenal gland: free of tumor 1) lymph node, hilar (0/1) : free of tumor	3	T3bN0M1(IV)

A214 : Kidney and ureter cancer tissues

No.	Coordinate		Sex	Age	Key Word	Histological Diagnosis	Grade	TNM Stage
8	B	5,6	m	71	RCC.conventional type	<p>1. Kidney, right, nephrectomy: renal cell carcinoma, conventional (clear cell) type,</p> <ul style="list-style-type: none"> 1) confined within renal capsule 2) extensive renovascular invasion resulting renal vein thrombosis 3) renal pelvis involvement 4) fuhrman's nuclear grade IV 5) resection margins, ureter and renal vein: free of tumor <p>2. Adrenal gland: free of tumor</p>	4	T3bN0M0 (III)
9	B	7,8	m	28	RCC.conventional type	<p>1. Kidney, right, radical nephrectomy: renal cell carcinoma, conventional (clear cell) type,</p> <ul style="list-style-type: none"> 1) confined within renal capsule 2) fuhrman's nuclear grade IV 3) no vascular invasion 4) extensive necrosis and multifocal calcification 5) resection margins, ureter and renal vessels: free of tumor 6) lymph nodes, regional (0/2) : free of tumor in all 2 lymph nodes <p>2. Adrenal gland: free of tumor</p>	4	T2N0M1 (IV)
10	B	9,10	f	74	urothelial ca	<p>1. Ureter, kidney, adrenal gland, right, nephroureterectomy: Invasive urothelial carcinoma,</p> <ul style="list-style-type: none"> 1) high grade (transitional cell carcinoma grade III) 2) extension to the proper muscle but not to the subserosa and serosal surface, arising from ureter <p>2. carcinoma in situ</p> <ul style="list-style-type: none"> 1) resection margins, ureter and renal vessel: free of tumor <p>3. Kidney: free of tumor</p> <p>4. Adrenal gland: free of tumor</p> <p>5. Ovary: no pathological diagnosis</p> <p>6. Fallopian tube: no pathological diagnosis</p>		T2N0M0 (II)

A214 : Kidney and ureter cancer tissues

No.	Coordinate		Sex	Age	Key Word	Histological Diagnosis	Grade	TNM Stage
11	C	1,2	m	44	RCC.papillary type	<p>1. Kidney and adrenal gland, right, nephrectomy and adrenalectomy: renal cell carcinoma, chromophil (papillary), with marked cystic change</p> <ol style="list-style-type: none"> 1) fuhrman grading II 2) confined within the capsule 3) gerotas' fascia: free of tumor 4) urethral margin: free of tumor 5) vessel margin: free of tumor 6) regional lymph node: free from the tumor metastasis <p>2. Adrenal gland: free of tumor</p>	2	T2N0M0 (II)
12	C	3,4	m	71	RCC.papillary type	<p>1. Kidney, right, radical nephrectomy: papillary renal cell carcinoma,</p> <ol style="list-style-type: none"> 1) confined within renal capsule 2) fuhrman's nuclear grade III 3) no vascular invasion 4) resection margin, ureter and renal vein: free of tumor <p>2. Adrenal gland: free of tumor</p>	3	T1bN0M0 (I)
13	C	5,6	m	52	RCC.papillary type	<p>1. Kidney, right, radical nephro-ureterectomy: papillary renal cell carcinoma,</p> <ol style="list-style-type: none"> 1) confined to the renal capsule 2) fuhrman's nuclear grade III 3) resection margin, ureter: free of tumor <p>2. Blood vessel: free of tumor</p> <p>3. Adrenal gland: free of tumor</p> <ol style="list-style-type: none"> 1) tissue submitted as lymph node: free of tumor without evidence of lymphoid tissue <p>* Result of immunohistochemistry: Cytokeratin 7 (-), Cytokeratin, High Molecular Weight (-), Cytokeratin 20 (-), Vimentin (+).</p>	3	T1aN0M0 (I)

A214 : Kidney and ureter cancer tissues

No.	Coordinate		Sex	Age	Key Word	Histological Diagnosis	Grade	TNM Stage
14	C	7,8	m	46	RCC.papillary type	<p>1. Kidney, right, radical nephrectomy: carcinoma showing predominant tubulopapillary feature with focal desmoplastic stroma, consistent with collecting duct carcinoma,</p> <ul style="list-style-type: none"> 1) extension to perirenal fat tissue 2) fuhrman's nuclear grade III 3) extensive lymphovascular permeation 4) no renal vein invasion <p>2. Ureter, surgical resection margin: free of tumor</p> <p>3. Adrenal gland: Massive lymphatic permeation of tumor in peri-adrenal fat tissue</p> <ul style="list-style-type: none"> 1) regional lymph node, precaval (1/2), retrocaval (5/5): (6/7) : tumor metastasis in 6 out of 7 lymph nodes <p>4.Kidney: renal cell carcinoma, papillary type(chromophil), type B.</p>	3	T3aN2M1 (IV)
15	C	9,10	m	79	urothelial ca	<p>1. Ureter with kidney, left, nephroureterectomy: papillary urothelial carcinoma,</p> <ul style="list-style-type: none"> 1) low grade (transitional cell carcinoma, grade II), without stromal invasion 2) multifocal urothelial dysplasia involving renal pelvis and ureter 3) chronic pyelonephritis, mild 4) resection margins, bladder and blood vessels: free of tumor <p>2. Adrenal gland: free of tumor</p>		TaNOM0 (0a)

A214 : Kidney and ureter cancer tissues

No.	Coordinate		Sex	Age	Key Word	Histological Diagnosis	Grade	TNM Stage
16	D	1,2	f	57	RCC.chromophobe type	<p>1. Kidney, right, radical nephrectomy: renal cell carcinoma, 1) nuclear grade II 2) focal extension to perirenal fat tissue without invasion to Gerota's fascia 3) no definite invasion to renal vein 4) hemorrhagic necrosis and subcapsular hematoma formation</p> <p>2. Ureter, adrenal gland right, lymph nodes, paraaortic (0/20): free of tumor</p> <p><Additional report> EM: Ultrastructural findings are compatible with renal cell carcinoma of chromophobe cell type showing numerous cytoplasmic vesicles of oval to round shape, ranging from 150-130nm in size. they tend to be concentrated adjacent to and surrounding the nucleus.</p>	2	T3aN0M0 (III)
17	D	3,4	f	36	RCC.chromophobe type	<p>1. Kidney, right, lobectomy: Chromophobe renal cell carcinoma, 1) confined within the renal capsule 2) no renal pelvis involvement</p> <p>2. renal vein and artery, ureter, adrenal gland : free of tumor</p>		T1bN0M0 (I)
18	D	5,6	f	55	RCC.chromophobe type	<p>1. Kidney, left, nephrectomy: Chromophobe renal cell carcinoma, 1) confined to renal capsule, without renal vein invasion 2) simple cyst 3) resection margin, ureter: free of tumor</p> <p>2. Adrenal gland: free of tumor 1) regional lymph node, paraaortic (0/18): free of tumor</p>		T1bN0M0 (I)

A214 : Kidney and ureter cancer tissues

No.	Coordinate		Sex	Age	Key Word	Histological Diagnosis	Grade	TNM Stage
19	D	7,8	m	74	RCC.chromophobe type	<p>1. Kidney, left, radical nephrectomy: renal cell carcinoma, chromophobe type,</p> <p>1) fuhrman's nuclear grade IV</p> <p>2) extension beyond renal capsule and to the hilar fat tissue</p> <p>3) no lymphatic and venous invasion</p> <p>4) no pelvocaliceal system invasion</p> <p>5) size: 8.5x7x7 cm</p> <p>6) resection margins, ureter and vessels: free of tumor</p> <p>7) lymph nodes, paraaortic (0/2): free of tumor</p> <p>2. Adrenal gland: free of tumor</p>		
20	D	9	f	36	ureter	Non-neoplastic from D3, 4		
21	D	10	f	70	ureter	Non-neoplastic from A9,10		
22	E	1,2	m	48	RCC.sarcomoid type	<p>1. Kidney, left, nephrectomy with adrenalectomy: renal cell carcinoma, chromophil(papillary) type with sarcomatoid differentiation,</p> <p>1) extension beyond renal capsule forming perihilar soft tissue mass</p> <p>2) fuhrman's nuclear grade: 4</p> <p>3) renal vein invasion</p> <p>4) no renal pelvis invasion</p> <p>5) size of tumor (10x7x5.5 cm)</p> <p>6) simple cysts</p> <p>7) resection margin, ureter: free of tumor</p> <p>8) lymph nodes, paraaortic(0/8), intraaortocaval(0/4) and retrocaval(0/3): free of tumor metastasis in all 15 nodes</p> <p>2. Adrenal gland: free of tumor</p> <p>*EM> Ultrastructure features are compatible with renal cell carcinoma: showing prominent cytoplasmic organelles, such as mitochondriae glycogens, RERs and rare lipid vacuoles within the cytoplasm.</p>		T3bN0M0 (III)

A214 : Kidney and ureter cancer tissues

No.	Coordinate		Sex	Age	Key Word	Histological Diagnosis	Grade	TNM Stage
23	E	3,4	f	66	RCC.sarcomoid type	<p>1.Kidney, left, radical nephrectomy: renal cell carcinoma, sarcomatoid, associated,</p> <ol style="list-style-type: none"> 1) conventional (clear cell) type 2) extension beyond renal capsule 3) fuhrman's nuclear grade IV 4) extensive lymphatic invasion 5) no renal vein invasion 6) no pelvocaliceal system involvement 7) resection margins, ureter and renal vessels: free of tumor 8) lymph nodes, paraaortic (9/11), aortocaval (1/1) and regional hilar (17/17): metastasis in 27 out of 29 nodes <p>2.Adrenal gland, diaphragm: free of tumor</p>		
24	E	5,6	f	58	RCC.sarcomoid type	<p>1. Kidney, left, radical nephrectomy: renal cell carcinoma, sarcomatoid,</p> <ol style="list-style-type: none"> 1) features of conventional (clear cell type) 2) extension to extrarenal perihilar soft tissue 3) renovascular invasion 4) pelvocaliceal invasion 5) perineural invasion 6) fuhrman's nuclear grade IV 7) size of tumor: 6x5x5 cm 8) resection margins, ureter and renal vessels: free of tumor <p>2. Adrenal gland: free of tumor</p>		
25	E	7,8	f	59	oncocytoma	<p>1. Kidney, right, radical nephrectomy: renal cell carcinoma, chromophobe,</p> <ol style="list-style-type: none"> 1) eosinophilic variant microscopically 2) confined within the renal capsule 3) grade 1 by fuhrman's nuclear grading 4) no pelvis involvement <p>2. Ureter, margin: free of tumor</p> <p>3. renal vein and artery: free of tumor</p> <p>4. Adrenal gland: free of tumor</p>	1	

A214 : Kidney and ureter cancer tissues

No.	Coordinate	Sex	Age	Key Word	Histological Diagnosis	Grade	TNM Stage
26	E 9	f	61	kideny	Non-neoplastic of cortex region from F1, 2		
27	E 10	f	2	kideny	Non-neoplastic of cortex region from F7, 8		
28	F 1,2	f	61	oncocytoma	1. Kidney, left, radical nephrectomy: renal oncocytoma with focally atypical cells, 1) resection margins, ureter and renal vessels: free of tumor 2. Adrenal gland: no pathological diagnosis		
29	F 3,4	f	62	oncocytoma	1. Kidney, right, nephrectomy: oncocytoma with renovascular invasion, 1) resection margins, ureter and renal vessels: free of tumor 2. Adrenal gland: no pathological diagnosis * Result of immunohistochemical stains: Cytokeratin 7 (-), E-cadherin (+). <Additional report> Result of Transmission Electron Microscope: blocks are made from formalin-fixed tumor. the sections show marked degeneration, but reveal numerous cytoplasmic mitochondriae, some with granular matrix. no vesicles or lipid droplet is identified.		
30	F 5,6	f	2	Wilm's tumor	1. Kidney and appendix, nephrectomy and appendectomy: Wilms' tumor without anaplasia, 1) limited within renal capsule 2) completely resected (stage I) 3) resection margins, blood vessels and ureter: free of tumor 2. Adrenal gland: free of tumor 1) lymph node, mesenteric (0/1) : free of tumor 3. Appendix, incidental appendectomy: no pathological diagnosis		

A214 : Kidney and ureter cancer tissues

No.	Coordinate		Sex	Age	Key Word	Histological Diagnosis	Grade	TNM Stage
31	F	7,8	f	2	Wilm's tumor	1. Kidney, left, nephrectomy: Wilms' tumor, 1) triphasic, epithelial predominant pattern 2) absence of anaplasia 3) confined to the renal capsule 2. Ureter and blood vessels: free of tumor 1) lymph nodes, hilar (0/2): free of tumor 2) lymph nodes, separately submitted as paraaortic (0/6): free of tumor 3. Adrenal gland: no pathological diagnosis 4. Appendix, appendectomy: lymphoid hyperplasia		
32	F	9	f	61	kideny	Non-neoplastic of medulla region from F1, 2		
33	F	10	f	2	kideny	Non-neoplastic of medulla region from F7, 8		
34	G	1,2	m	2	Wilm's tumor	1. Kidney, left, radical nephrectomy: Wilms' tumor, triphasic, 1) limited to kidney with intact renal capsule (NWTS stage I) without anaplasia and without renal vein invasion 2. Ureter, resection margin: free of tumor 1) lymph node, hilar: (0/11): free of tumor 3. Adrenal gland: free of tumor 4. Appendix, incidental appendectomy: no pathological diagnosis		
35	G	3,4	f	63	angiomyolipoma	1. Kidney, left, radical nephrectomy: angiomyolipoma, 1) capsular involvement 2. Ureter: no pathological diagnosis 3. Adrenal gland, left: no pathological diagnosis		

A214 : Kidney and ureter cancer tissues

No.	Coordinate		Sex	Age	Key Word	Histological Diagnosis	Grade	TNM Stage
36	G	5,6	f	67	angiomyolipoma	1. Kidney, right, nephrectomy: angiomyolipoma, 1) focally extending beyond renal capsule 2) confined to gerota's fascia 2. Ureter, resection margin: free of tumor 3. renal artery and vein: free of tumor 4. Adrenal gland: free of tumor * Result of immunohistochemistry: Vimentin (+), Actin (+), Desmin (+), Low MW Cytokeratin (-), EMA (-), Factor VII I(-), CD31 (-), S-100 (-).		
37	G	7,8	f	58	angiomyolipoma	1. Kidney, right, radical nephrectomy: angiomyolipoma, 2. Ureter: no pathological diagnosis 3. Adrenal gland, right: no pathological diagnosis		