

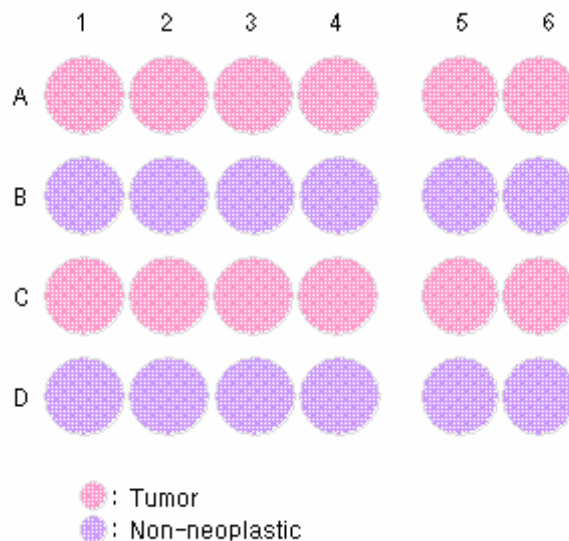
Specifications:

- No. of cases: 12
- Tissue type: Test slide, various cancer tissues with corresponding normal tissues
- No. of spots: 12 spots from each cancer case (12 spots)
12 non-neoplastic spots (12 spots)
- Total spots: 24
- Corresponding normal tissues with cancers: Yes
- Diameter: 1.0 mm

Documents:

- Product specification: layout, summary of tissue spots
- H&E stained images
- Detailed pathological information

Layout:



(formalin fixed)

For research use only

Summary of tissue spots

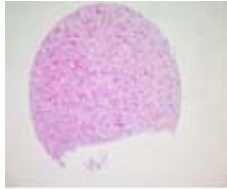
No	Coordinate	Sex	Age	Specimen	Key Word	
1	A B*	1	f	55	Brain	glioblastoma
2	A B*	2	m	70	Skin	squamous cell carcinoma
3	A B*	3	m	67	Esophagus	squamous cell carcinoma
4	A B*	4	m	61	Lung	adenocarcinoma
5	A B*	5	f	37	Thyroid gland	papillary carcinoma
6	A B*	6	f	32	Breast	infiltrating ductal carcinoma
7	C D*	1	m	39	Liver	hepatocellular carcinoma
8	C D*	2	m	62	Stomach	adenocarcinoma
9	C D*	3	f	80	Signoid colon	adenocarcinoma
10	C D*	4	m	51	Kidney	renal cell carcinoma
11	C D*	5	f	26	Ovary	mucinous cystadenocarcinoma
12	C D*	6	f	52	Cervix	squamous cell carcinoma

* : corresponding non-neoplastic tissues

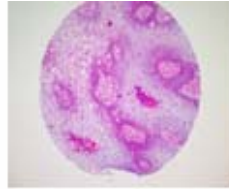
(formalin fixed)

For research use only

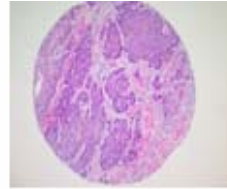
**QC sheet_LOT#132120506291
Hematoxylin and Eosin staining**



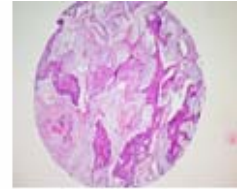
A1



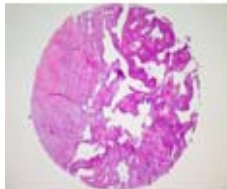
A2



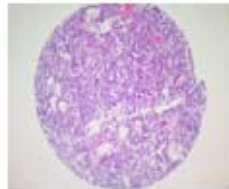
A3



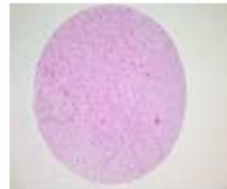
A4



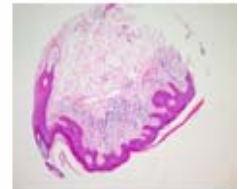
A5



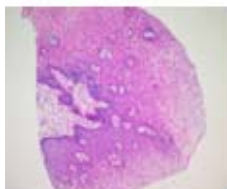
A6



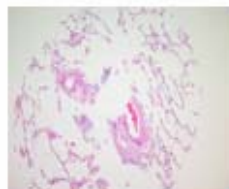B1



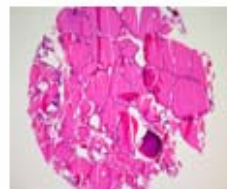B2



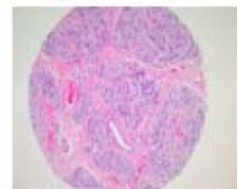
B3



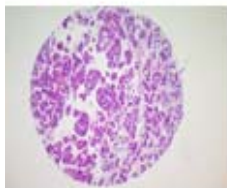
B4



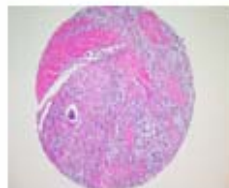
B5



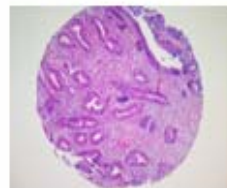
B6



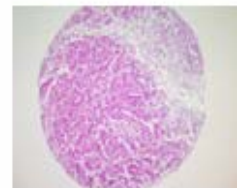
C1



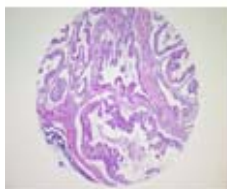
C2



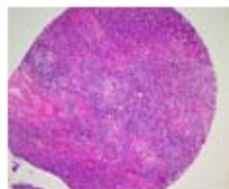
C3



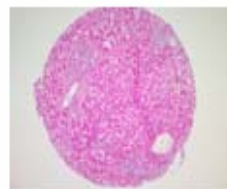C4



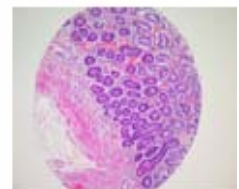
C5



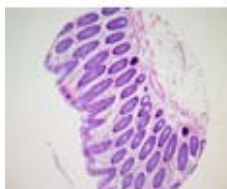C6



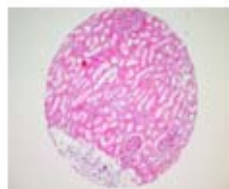
D1



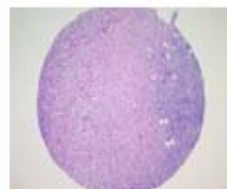
D2



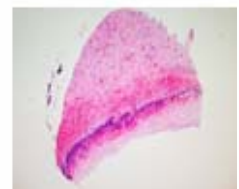
D3



D4



D5



D6

A701(III): Test slide, Various cancer tissues with corresponding normal tissues

No	Coordinate	Sex	Age	Key Word	Histological Diagnosis	
1	A	1	f	55	brain: glioblastoma	Brain, left parietooccipital area, removal: astrocytoma grade 4 (glioblastoma).
2	B	1	f	55	non-neoplastic	non-neoplastic from A1
3	A	2	m	70	skin:squamous cell carcinoma	Skin, buttock, left, wide excision: 1) invasive squamous cell carcinoma, moderately differentiated 2) resection margins, lateral and base: free of tumor.
4	B	2	m	70	non-neoplastic	non-neoplastic from A2
5	A	3	m	67	esophagus: squamous cell carcinoma	Esophagus, Ivor Lewis operation: 1) squamous cell carcinoma, poorly differentiated - ulceroinfiltrative type - extending through muscle layer and focally extending to adventitia - occasional lymphatic permeation 2) resection margin, proximal: presence of squamous cell carcinoma in situ within 1mm away from the margin 3) resection margin, distal: free of tumor 4) regional lymph nodes, periesophageal(1/14): tumor metastasis in 1 out of 14 nodes 5) regional lymph nodes, separately submitted, peripancreatic(0/1), common hepatic(0/2), subcarinal(0/5), left paracardial(2/4), celiac(0/4), lesser curvature(0/4): (0/20): tumor metastasis in 2 out of 20 nodes.
6	B	3	m	67	non-neoplastic	non-neoplastic from A3
7	A	4	m	61	lung: adenocarcinoma	Lung, left upper lobe, lobectomy: 1) adenocarcinoma, moderately differentiated, acinar type - tumor size 5.5x5.5x4cm (>3cm) - with extension to mediastinal pleura - necrosis less than 10% 2) adjacent parenchyme: obstructive pneumonitis 3) resection margin, bronchial and vessel: free of tumor 4) lymph nodes, anterior mediastinal(0/3), A-P window(1/5), peribronchial LN(1/6):(2/15): metastatic adenocarcinoma in 1 out 15 nodes 5) soft tissue, labelled as "right paratreacheal LN": free of tumor.
8	B	4	m	61	non-neoplastic	non-neoplastic from A4
9	A	5	f	37	thyroid gland : papillary carcinoma	Thyroid gland, total thyroidectomy: papillary carcinoma with 1) extension to the extrathyroidal soft tissue and skeletal muscle 2) lymphovascular invasion 3) lymph nodes(11/13): metastasis in 11 out 13 nodes.
10	B	5	f	37	non-neoplastic	non-neoplastic from A5

A701(III): Test slide, Various cancer tissues with corresponding normal tissues

No	Coordinate		Sex	Age	Key Word	Histological Diagnosis
11	A	6	f	32	breast: infiltrating ductal carcinoma	Breast, left, lumpectomy: 1) infiltrating ductal carcinoma, nuclear grade 1(poorly differentiated), Histologic grade III without intraductal component 2) lymph node, regional(0/1): free of tumor 3) immunohistochemical staining results: ER,PR (-), C erb B2(+).
12	B	6	f	32	non-neoplastic	non-neoplastic from A6
13	C	1	m	39	liver: hepatocellular carcinoma	1. Liver, left, extended lobectomy: hepatocellular carcinoma, left lobe with 1) size: 12x12x9cm 2) Edmondson-Steiner grade III 3) compact and trabecular histologic pattern 4) single nodular type with perinodal spread 5) expanding growth pattern 6) extensive necrosis: more than 70% of total volume 7) frequent venous invasion 8) intact intrahepatic resection margin(safety margin 1cm) 9) chronic hepatitis, B-viral, with mild inflammatory activity (Grade II) and septal fibrosis(Stage III) 2. Gallbladder, separately submitted: autolytic change without tumor extension.
14	D	1	m	39	non-neoplastic	non-neoplastic from C1
15	C	2	m	62	stomach: adeno carcinoma	Stomach, radical subtotal gastrectomy: 1) signet ring cell carcinoma with mucin pool formation (about 30-40% of tumor), ulceroinfiltrative type, and extension to the perigastric fat tissue with exposure to free serosal surface 2) multifocal lymphovascular permeation 3) resection margins, proximal and distal: free of tumor 4) lymph nodes, No.3(13/16), No.4(3/3), No.5(1/1), No.6(10/10), No.7(2/2) and No.8(4/4):(33/36): tumor metastasis to 33 out of 36 lymph nodes with perinodal soft tissue extension.
16	D	2	m	62	non-neoplastic	non-neoplastic from C2
17	C	3	f	80	sigmoid colon : adenocarcinoma	Sigmoid colon, segmental resection: 1) adenocarcinoma, moderately differentiated, ulcerative type with extension to the pericolic fat tissue 2) obstructive colitis 3) resection margins, proximal and distal: free of tumor 4) lymph nodes, regional(1/24): metastatic adenocarcinoma in 1 out of 24 lymph nodes.
18	D	3	f	80	non-neoplastic	non-neoplastic from C3

A701(III): Test slide, Various cancer tissues with corresponding normal tissues

No	Coordinate	Sex	Age	Key Word	Histological Diagnosis	
19	C	4	m	51	kidney: renal cell carcinoma	Kidney, right, radical nephro-ureterectomy: 1) papillary renal cell carcinoma, confined to the renal capsule Fuhrman's nuclear grade III. 2) resection margin, ureter: free of tumor 3) blood vessel: free of tumor 4) adrenal gland: free of tumor 5) tissue submitted as lymph node: free of tumor without evidence of lymphoid tissue 6) result of immunohistochemistry: Cytokeratin 7(-), Cytokeratin,High Molecular Weight(-), Cytokeratin 20(-), Vimentin(+).
20	D	4	m	51	non-neoplastic	non-neoplastic from C4
21	C	5	f	26	ovary: mucinous cystadenocarcinoma	Ovary and fallopian tube, left, salpingoophorectomy: 1) ovary: mucinous cystadenocarcinoma confined within the capsule 2) fallopian tube: free of tumor 3) ovary, right, partial oophorectomy: mesothelial hyperplasia without tumor 4) soft tissue, right and left, paracolic gutter, right retroperitoneum: chronic nonspecific inflammation without tumor 5) omentum, partial omentectomy: chroni nonspecific inflammation with mesothelial hyperplasia.
22	D	5	f	26	non-neoplastic	non-neoplastic from C5
23	C	6	f	52	cervix: squamous cell carcinoma	Uterus including both adnexa, total abdominal hysterectomy with bilateral salpingoophorectomy: 1) cervix: Invasive squamous cell carcinoma, large cell, non-keratinizing type without lymphatic invasion (depth of invasion:8/15mm) 2) endometrium: atrophy 3) myometrium: adenomyosis 4) ovaries, bilateral: no pathological diagnosis 5) fallopian tubes, bilateral: no pathological diagnosis 6) parametriums, bilateral: free of tumor 7) vaginal cuff: free of tumor 8) lymph nodes, left, parametrial(0/2), right pelvic(0/4) and left pelvic(0/3): free of tumor metastasis in all 9 nodes.
24	D	6	f	52	non-neoplastic	non-neoplastic from C6